

Risk Stratification for Equivocal PI-RADS™ 3 Results: Can Micro-Ultrasound Help Determine Which Men to Biopsy?

Georg Salomon¹, Giovanni Lughezzani², Ander Astobieta³, Frédéric Staerman⁴, Eric Klein⁵,
Robert Abouassaly⁵, Ahmed El-Shefai⁵, Gregg Eure⁶, Sangeet Ghai⁷

¹Martini Klinik, Prostate Cancer Center, University Hospital Hamburg, Germany, ²Instituto Clinico Humanitas, Rozzano, Italy, ³Urología Clínica, Clínica IMQ Zorrotzaurre, Spain, ⁴Polyclinique Reims-Bezannes, Reims, France, ⁵Glickman Urological Institute, Cleveland Clinic, Cleveland, USA, ⁶Urology of Virginia, Virginia Beach, USA, ⁷Joint Department of Medical Imaging, University Health Network, University of Toronto, Toronto, Canada

INTRODUCTION

Reducing unnecessary prostate biopsy procedures is an important clinical goal to minimize patient stress, minimize risk of infection and overtreatment, and reduce overall healthcare cost. Prostate imaging with mpMRI shows considerable utility in patient risk stratification however indeterminate or equivocal results pose a diagnostic challenge. Alternately, **micro-ultrasound** operates at high frequencies (**29 MHz**) and provides real-time, office-based imaging with high resolution (down to **70 microns**) and may help guide evidence-based decision-making for indeterminate results.

OBJECTIVE

This study seeks to identify the potential of **micro-ultrasound** as an additional tool for risk stratification with patients who have equivocal mpMRI results.

METHODS:

- Retrospective analysis was performed on **83** patients, each with MRI findings of maximum **PI-RADS 3** (equivocal), across 7 international urological sites
- PRI-MUS™** (prostate risk identification using micro-ultrasound) protocol¹ was used to identify suspicious regions, locate targets (**PRI-MUS ≥ 3**) and biopsies were performed using the **ExactVu™** micro-ultrasound system (**ExactVu™**, **Exact Imaging**)
- Overall maximum **PRI-MUS** score for each subject was used to determine whether the case was non-suspicious (**PRI-MUS 1** or **2**), equivocal (**PRI-MUS 3**), or suspicious (**PRI-MUS 4** or **5**)
- Overall Gleason sum was used as a reference; however there was no standard biopsy procedure due to varying number of systematic and targeted samples

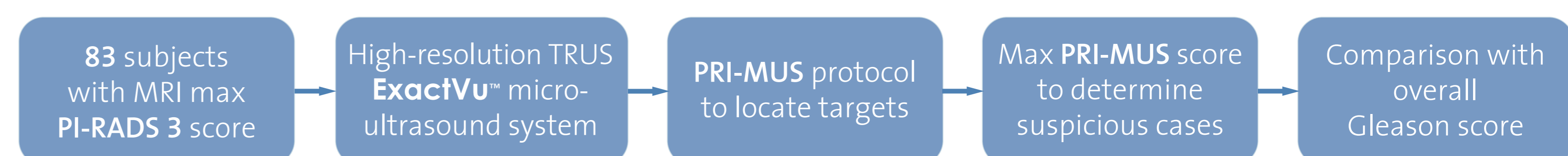

Figure 1: Study procedure using micro-ultrasound PRI-MUS score to indicate suspicion levels on equivocal mpMRI subjects

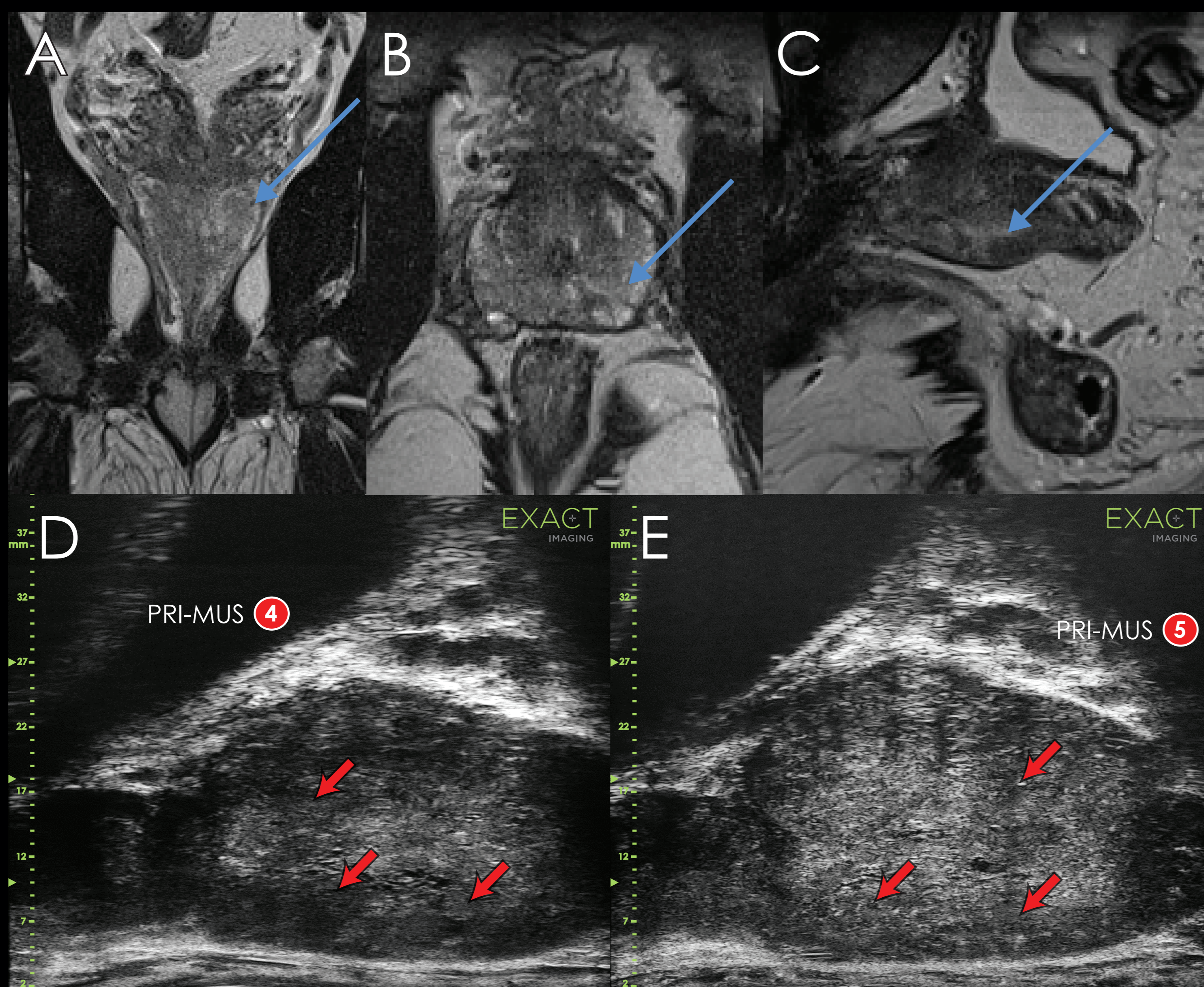


Figure 2: Comparative MRI and micro-ultrasound images of index lesion (Reproduced from Ghai and Van der Kwast, Urol Case Reports 2018).

(A) Coronal T2 MRI, (B) Axial T2 MRI, (C) Sagittal T2 MRI, (D) Parasagittal micro-ultrasound of left lateral edge of prostate, (E) Parasagittal micro-ultrasound of left medial edge of lesion. mpMRI reported a **PI-RADS 3** lesion in the left base-mid aspect of the prostate as indicated by the **blue arrows**. The micro-ultrasound images show mottled tissue consistent with **PRI-MUS 4**, along with suspicious shadowing consistent with **PRI-MUS 5** in the left mid-base aspects of the prostate (**red arrows**). Pathology confirmed a **Gleason 7 (4+3)** in the left mid aspect of the prostate and a **Gleason 7 (3+4)** in the left base aspect of the prostate.

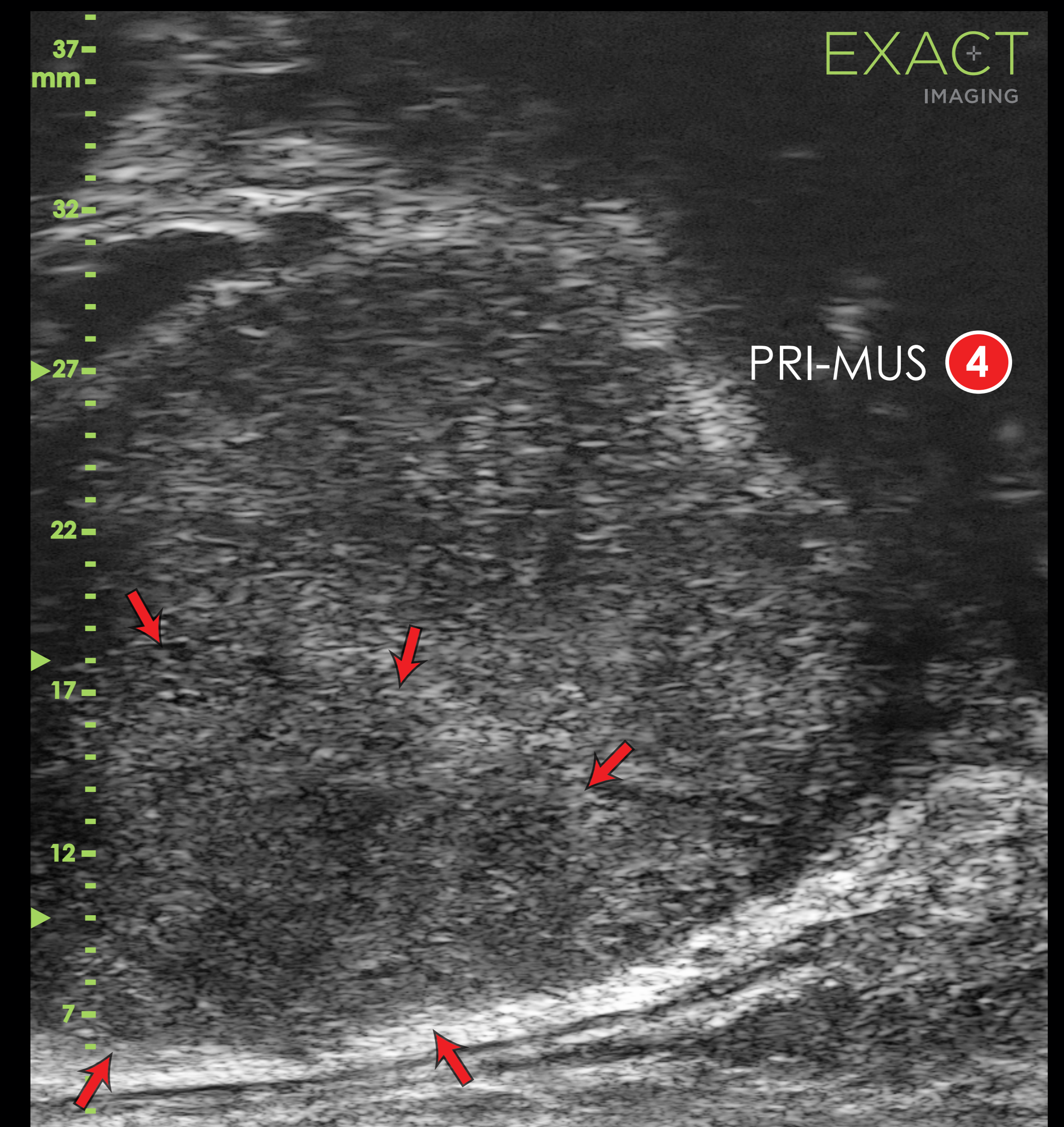


Figure 3: Parasagittal micro-ultrasound image of a **PI-RADS 3** lesion in the right base medial aspect of the prostate.

The micro-ultrasound image shows a smudgy-hypoechoic tissue consistent with **PRI-MUS 4** (**red arrows**). Pathology confirmed a **Gleason 7** in the right base medial aspect of the prostate.

RESULTS:

- + 83 subjects were included, each with 1 biopsy
- + Overall detection rate was 55% (46/83) with 23% (19/83) csPCa (GG>1)
 - ▶ Non-suspicious micro-ultrasound imaging reduced the risk of finding csPCa by more than half to 10% (1/10)
 - ▶ Equivocal micro-ultrasound imaging provided little additional information with detection rate 17% (3/18)
 - ▶ Suspicious micro-ultrasound imaging resulted in 17% increase in detection rate to 27% (15/55) over mpMRI

Micro-Ultrasound Identified Cases

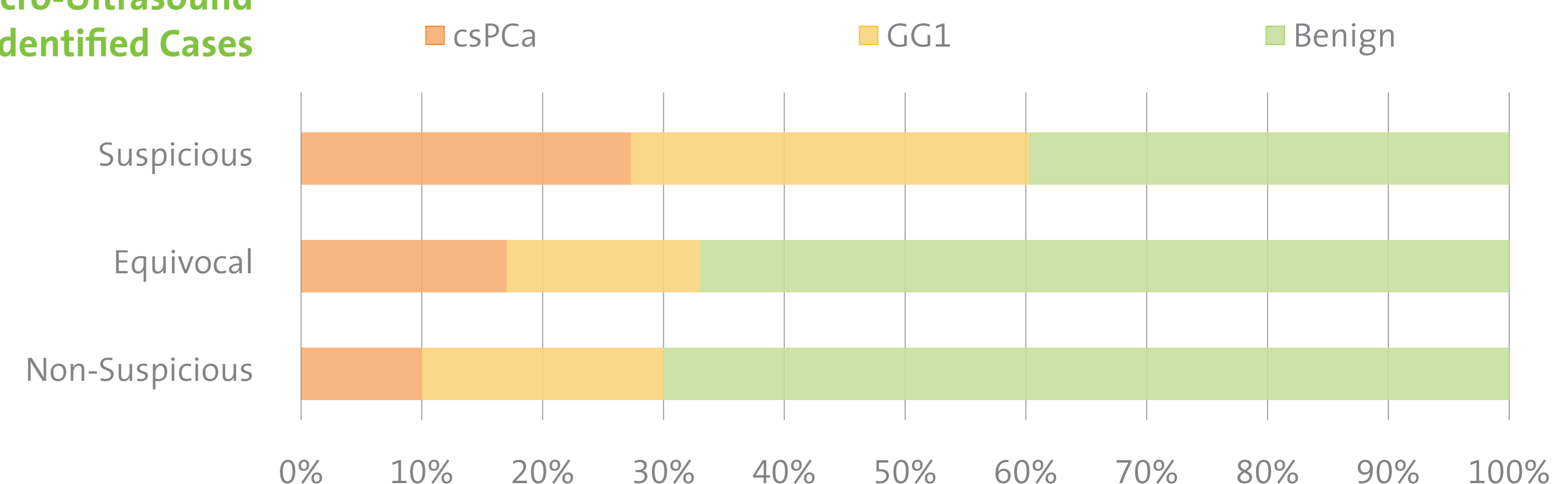


Figure 4: Detection rate on micro-ultrasound-identified non-suspicious, equivocal, and suspicious cases for indeterminate mpMRI subjects

CONCLUSIONS:

- Micro-ultrasound imaging along with the **PRI-MUS** protocol appear to provide additional information in equivocal mpMRI cases
- Synergies between micro-ultrasound imaging and existing clinical risk indicators such as PSA or family history may help advise patients on the necessity of a biopsy

REFERENCES

1. Ghai S, Eure G, Fradet V, et al: Assessing Cancer Risk on Novel 29 MHz Micro-Ultrasound Images of the Prostate: Creation of the Micro-Ultrasound Protocol for Prostate Risk Identification. J. Urol. 2016; 196: 562-569.